INFORMATION SHEET

Serial dilution (ten-fold) and sensitivity

A ten-fold dilution reduces the concentration of a solution by a factor of ten (one-tenth of the original solution). In a serial dilution, this process is repeated, such that each tube is one-tenth the concentration of the previous solution. The **sensitivity** of a test measures the probability of detection. A highly sensitive test can measure very small amounts of a substance in solution, while a less sensitive test can only detect larger quantities of a substance present in solution.

A TEN-FOLD SERIAL DILUTION



[Adapted: <https://accounts.smccd.edu/case/biol240/dilutions.html>]

Colour tests are tests that determine the concentration of a substance in a solution with the aid of a colour reagent. **Alcohol Detection Solution (ADS)** is one such reagent that is able to detect the presence of alcohol in a solution. The reagent itself is red. When added to a solution, the following colours can be expected:

Concentration (alcohol units)	**Colour**
High	Blue
Average	Green
Low (negligible)	Yellow

Consumption of alcohol during pregnancy and breastfeeding is not recommended. **Foetal Alcohol Syndrome (FAS)** is caused when a pregnant woman drinks alcohol. The alcohol can reach any part of her body and the unborn baby within 20 minutes after consumption. Alcohol is toxic for the unborn baby and it may damage any of the organs, although the developing brain and nervous system are the most vulnerable. For this reason, babies exposed to alcohol during pregnancy are at risk of permanent brain damage.

Excessive or daily intake of alcohol by breastfeeding mothers is also not recommended, but having an occasional alcoholic drink has not been shown to be harmful to a breastfed infant. A single exposure of alcohol from breast milk may have a mildly sedating effect or alter the odour or taste of the breast milk. Ideally, it is best to avoid breastfeeding for about 2 hours after drinking one alcoholic beverage.

[Adapted: <http://www.fasfacts.org.za>]

IEB Copyright © 2019

Visualisation of the brain of a normal individual (A) and two with FAS (B, C) showing permanent loss of the tissue indicated by the arrows (portions of the corpus callosum).

NORMAL

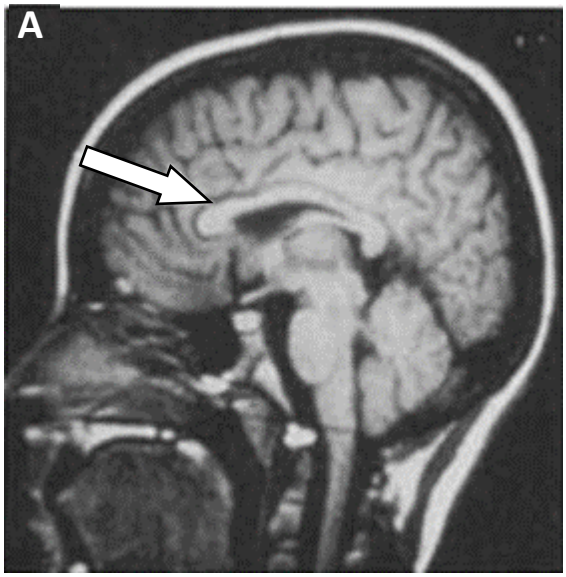

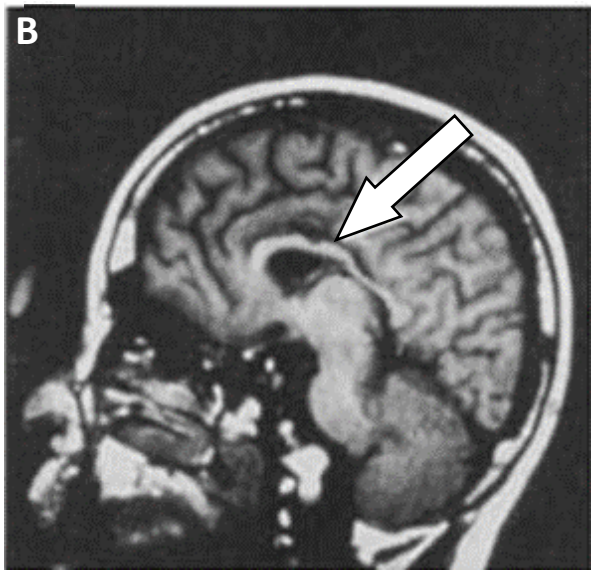

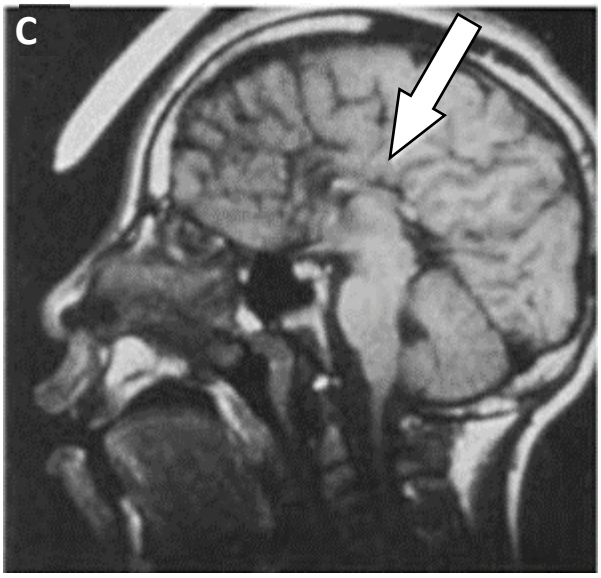

FAS **FAS**

Images courtesy of Dr. S. Mattson

IEB Copyright © 2019